

Laceration Zones

■ Consider ending bout

■ Careful evaluation of depth

- **One – tarsal plate, lacrimal sac**
- **Two - vermilion border**
- Three – supraorbital / supratrochlear nerves
- Four – nasal bridge, **FRACTURE**
- Five – infraorbital nerve
- Six – nasolabial fold with facial artery
- Seven — superficial temporal artery, facial nerve (at the zygomatic bone)
- **Eight - facial artery at masseter**
- **Nine – mental nerve**

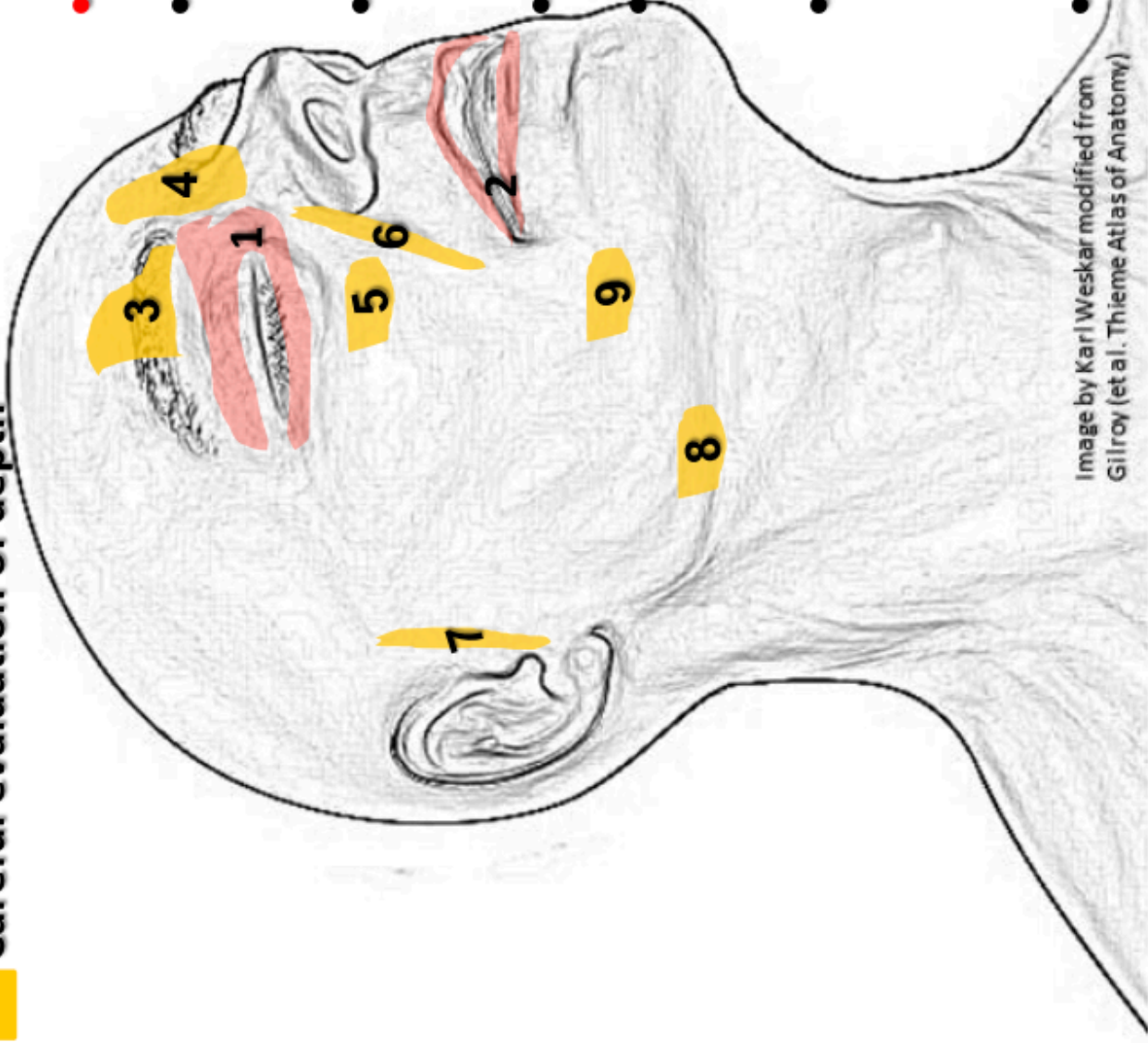


Image by Karl Weskar modified from Gilroy (et al. Thieme Atlas of Anatomy)