

## Laceration Zones

**Consider ending bout**  
**Careful evaluation of depth**

- **One – tarsal plate, lacrimal sac**
- **Two - vermilion border**
- **Three – supraorbital / supratrochlear nerves**
- **Four – nasal bridge, FRACTURE**
- **Five – infraorbital nerve**
- **Six – nasolabial fold with facial artery**
- **Seven — superficial temporal artery, facial nerve (at the zygomatic bone)**
- **Eight - facial artery at masseter**
- **Nine – mental nerve**

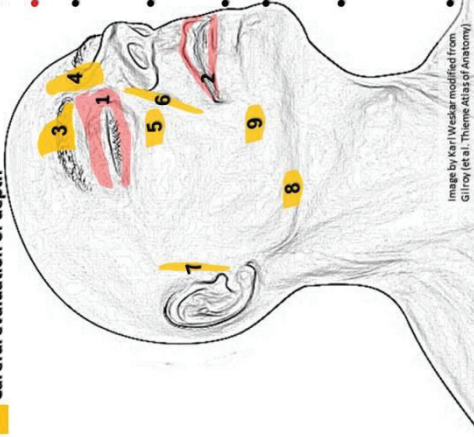


Image by Karl Weskar modified from Gilroy (et al., Theme Atlas of Anatomy)

Larry Lovelace, DO, FACEP & Daniel O'Donoghue, PA-C, PhD

## Laceration Zones

**Consider ending bout**  
**Careful evaluation of depth**

- **One – tarsal plate, lacrimal sac**
- **Two - vermilion border**
- **Three – supraorbital / supratrochlear nerves**
- **Four – nasal bridge, FRACTURE**
- **Five – infraorbital nerve**
- **Six – nasolabial fold with facial artery**
- **Seven — superficial temporal artery, facial nerve (at the zygomatic bone)**
- **Eight - facial artery at masseter**
- **Nine – mental nerve**

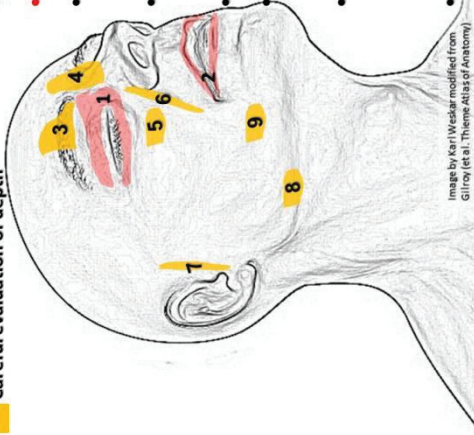


Image by Karl Weskar modified from Gilroy (et al., Theme Atlas of Anatomy)

Larry Lovelace, DO, FACEP & Daniel O'Donoghue, PA-C, PhD

## Laceration Zones

**Consider ending bout**  
**Careful evaluation of depth**

- **One – tarsal plate, lacrimal sac**
- **Two - vermilion border**
- **Three – supraorbital / supratrochlear nerves**
- **Four – nasal bridge, FRACTURE**
- **Five – infraorbital nerve**
- **Six – nasolabial fold with facial artery**
- **Seven — superficial temporal artery, facial nerve (at the zygomatic bone)**
- **Eight - facial artery at masseter**
- **Nine – mental nerve**

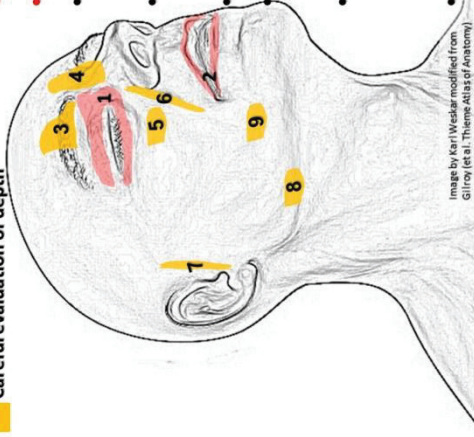

Image by Karl Weskar modified from Gilroy (et al., Theme Atlas of Anatomy)

Larry Lovelace, DO, FACEP & Daniel O'Donoghue, PA-C, PhD

## Laceration Zones

**Consider ending bout**  
**Careful evaluation of depth**

- **One – tarsal plate, lacrimal sac**
- **Two - vermilion border**
- **Three – supraorbital / supratrochlear nerves**
- **Four – nasal bridge, FRACTURE**
- **Five – infraorbital nerve**
- **Six – nasolabial fold with facial artery**
- **Seven — superficial temporal artery, facial nerve (at the zygomatic bone)**
- **Eight - facial artery at masseter**
- **Nine – mental nerve**

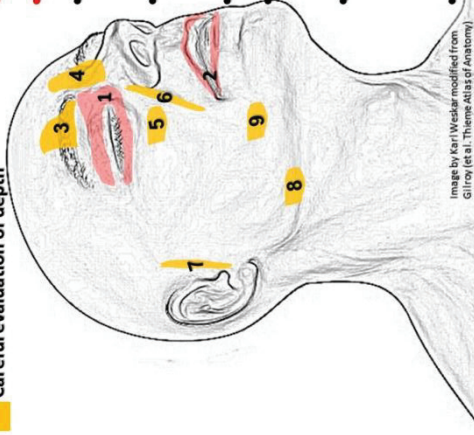
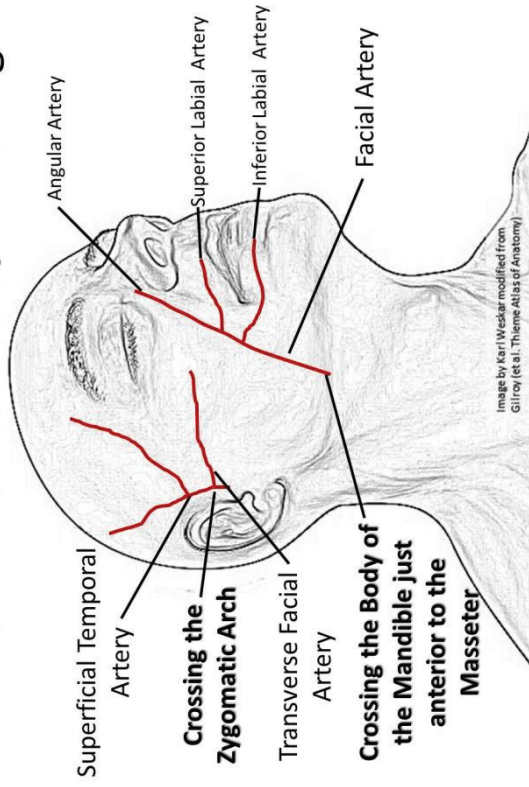


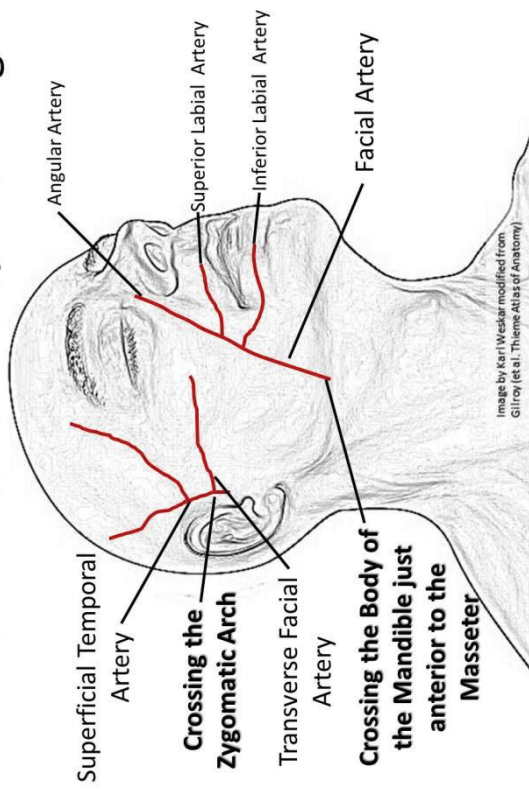
Image by Karl Weskar modified from Gilroy (et al., Theme Atlas of Anatomy)

Larry Lovelace, DO, FACEP & Daniel O'Donoghue, PA-C, PhD

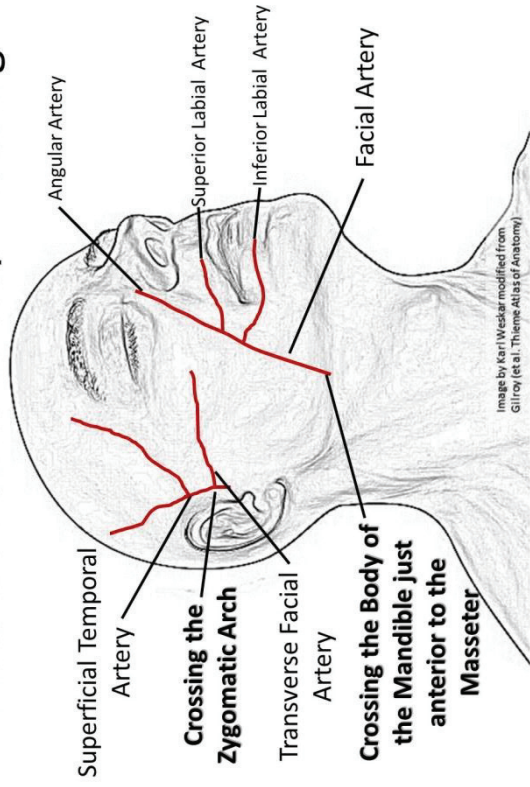
## Pressure Points to Stop Bleeding



## Pressure Points to Stop Bleeding



## Pressure Points to Stop Bleeding



## Pressure Points to Stop Bleeding

